



Original Article

Primary nonunion of intertrochanteric fractures of femur: An analysis of results of valgization and bone grafting

IK Dhammi, AK Jain, AP Singh, Rehan-Ul-Haq, P Mishra, S Jain

ABSTRACT

Background: Nonunion of intertrochanteric fractures is uncommon because there is excellent blood supply and good cancellous bone in the intertrochanteric region of the femur. A diagnosis of primary intertrochanteric nonunion is made when at least 15 weeks after the fracture there is radiological evidence of a fracture line, with either no callus (atrophic) or with callus that does not bridge the fracture site (hypertrophic). There is only one published series that exclusively describes seven primary nonunions of intertrochanteric fractures. The aim of the present study was to analyze the results of internal fixation, valgization with 135° dynamic hip screw (DHS), and bone grafting in patients with primary nonunion of intertrochanteric fractures.

Materials and Methods: Eighteen patients with primary intertrochanteric nonunion were included in the study; 16 were male and 2 were female. The age range was 30–70 years (mean: 46.9 years). The mean duration since index injury was 8.5 months (range: 4–18 months). As per the AO classification, the fractures were 31A 1.1 (n=1), 1.2 (n=1), 2.2 (n=3), 2.3 (n=9), and 3.3 (n=4). Three patients had hypermobile nonunion and 15 had stiff nonunion. The surgical principle was excision of pseudarthrosis, if present (n=3); freshening of the bone ends; stable fixation with 135° DHS, with good proximal purchase; bone grafting; and valgization.

Results: Union was achieved in all patients at an average of 5.62 months (range: 4–7 months). The Harris hip score improved from 38 points preoperatively to 86 postoperatively at healing. The average limb shortening improved by 2 cm (range: 1.5 cm–3 cm). There was no infection and pain at the hip at final follow-up in any of the cases. All patients were subjectively satisfied with the outcome. All were capable of full weight bearing on their affected limb.

Conclusion: Union in primary nonunion of intertrochanteric fractures in physiologically young patients with a well-preserved femoral head and good bone stock can be achieved with internal fixation, valgization, and grafting procedures.

Key words: Bone grafting, intertrochanteric fractures, valgization

INTRODUCTION

Nonunion of intertrochanteric fractures is uncommon because there is excellent blood supply and good cancellous bone in the intertrochanteric region of the femur.¹ Most intertrochanteric fractures treated by conservative methods or internal fixation heal.^{2,3}

Occasionally, nonunion or early failure of fracture fixation occurs, the reasons being delayed treatment, unfavorable fracture patterns, poor bone quality, or suboptimal internal fixation.⁴⁻⁸ Nonunion results in pain and functional disability.⁷ Literature is sparse regarding primary intertrochanteric nonunions and its treatment. Revision internal fixation and bone grafting has been reported in fixation failures in very few series and results have generally been encouraging.⁸⁻¹¹ In the elderly, hip arthroplasty is the preferred treatment for intertrochanteric nonunion with damaged articular surface, or inadequate bone stock, but in the physiologically young with good bone quality preservation of the femoral head is preferred.¹ This study aims to evaluate the results of internal fixation, valgization with 135° dynamic hip screw (DHS), and bone grafting in 18 patients with primary nonunion of intertrochanteric fractures.

MATERIALS AND METHODS

We carried out a retrospective analysis of 18 patients with primary intertrochanteric nonunion treated in our

Department of Orthopedics, University College of Medical Sciences and Guru Teg Bahadur Hospital, Dilshad Garden, Delhi, India

Address for correspondence: Dr. IK Dhammi,

Department of Orthopedics, University College of Medical Sciences and Guru Teg Bahadur Hospital, Dilshad Garden, Delhi - 110 095, India.

E-mail: drikdhammi@gmail.com

Access this article online	
Quick Response Code:	Website: www.ijoonline.com
	DOI: 10.4103/0019-5413.87122

institution during 1993–2007. Sixteen patients were male and two were female. The age range was 30–70 years (mean: 46.9 years); five patients were 60 years or above and the rest were below 60 years [Table 1]. The right limb

was involved in 11 and the left in 7 patients. The mean duration since the index injury was 8.5 months (range: 4–18 months). As per the AO classification,¹² the reference fractures were 31 A 1.1 (n=1), 1.2 (n=1), 2.2 (n=3), 2.3 (n=9), and 3.3 (n=4). Patients with osteoarthritis and implant failures were excluded from the study. Nonunion was diagnosed when the patient had pain on ambulation, inability to bear weight on the affected limb, clinically documented motion between fragments, absent active straight leg raising test, demonstrable telescoping, change of neck–shaft angle on anteroposterior abduction–adduction views on X-ray, radiolucent defect at the fracture site, and a delay of 4 months or more after the initial trauma. [Figures 1-3] All the patients were originally treated nonoperatively: 11 had conservative management in the form of traction (n=7)/hip spica (n=4), 4 patients had no treatment, and 3 patients took treatment from osteopaths. Each case was evaluated clinically and radiographically.

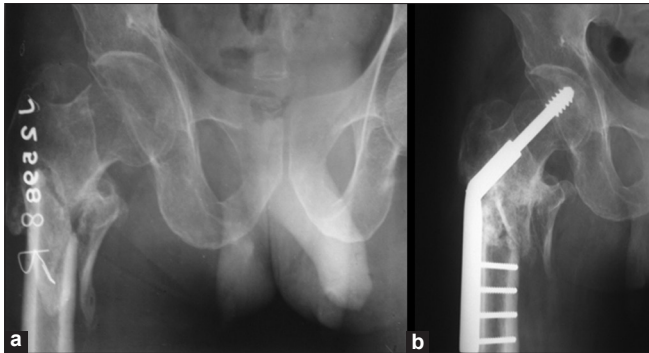


Figure 1: X-ray right hip anteroposterior view (a) 4 months after injury showing sclerotic margins. (b) Follow-up X-ray after 1 year showing DHS in situ and union at the fracture site

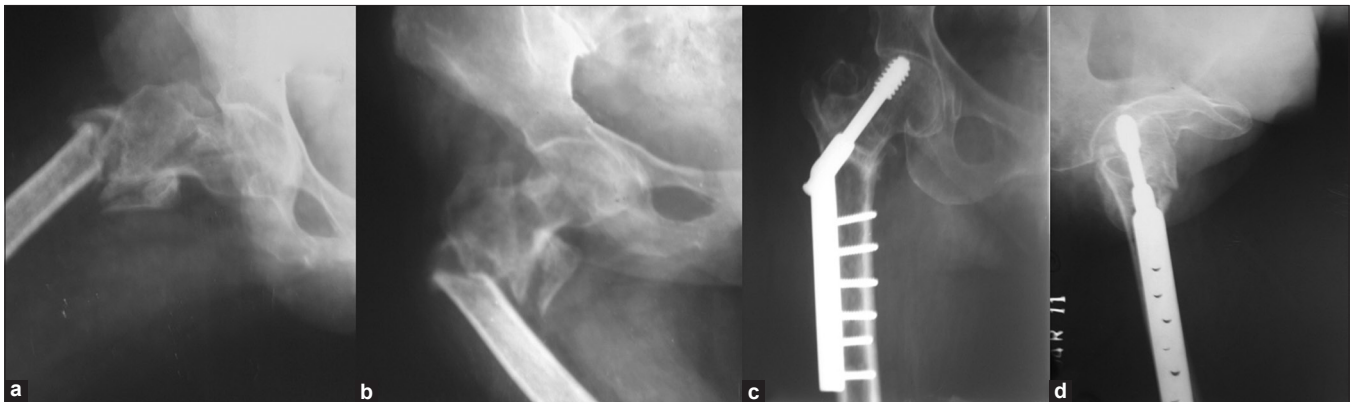


Figure 2: Abduction–adduction anteroposterior X-rays (a and b) showing hypermobile nonunion in a 62-year-old female (c and d) X-rays anteroposterior and lateral views at 6 months showing union

Table 1: Clinical details of the patients

Age (in years)	Sex	Duration from injury (in months)	Treatment taken	Side	N/S angle (in degrees)	Type AO	Treatment	N/S angle after union (in degrees)	Varus collapse	F/U (in years)
65	F	6	None	R	90	2.3	DHS+BG+VAL	130	5°	5
50	M	6	None	R	106	2.3	DHS+BG+VAL	130	5°	5
35	M	5	None	L	104	2.3	DHS+BG+VAL	130	5°	7
36	M	6	None	R	106	1.1	DHS+BG+VAL	125	10°	7
50	M	6	Osteopath	R	102	2.2	DHS+BG+VAL	130	5°	2
45	M	7	Traction	L	112	3.3	DHS+BG+VAL	130	5°	2
36	M	18	Traction	L	102	2.3	DHS+BG+VAL	125	10°	6
38	M	4.6	Conservative	L	106	2.3	DHS+BG+VAL	130	5°	7
30	M	4	Conservative	L	104	2.2	DHS+BG+VAL	125	10°	4.4
40	M	5.6	Conservative	R	98	2.3	DHS+BG+VAL	130	5°	7
35	M	6	Conservative	R	102	3.3	DHS+BG+VAL	125	10°	8
38	M	12	Conservative	R	106	2.2	DHS+BG+VAL	130	5°	7
40	M	5	Conservative	L	116	2.3	DHS+BG+VAL	125	10°	5
60	F	12	Conservative	R	106	3.3	DHS+BG+VAL	125	10°	5
62	M	12	Conservative	R	92	1.2	DHS+BG+VAL	130	5°	6
70	M	7	Osteopath	L	100	2.3	DHS+BG+VAL	130	5°	5
60	M	5	Osteopath	R	104	3.3	DHS+BG+VAL	115	20°	6
55	M	5	Conservative	R	100	2.3	DHS+BG+VAL	120	5°	2.2

N/S = Neck shaft, R = Right, L = Left, DHS = Dynamic hip screw, BG = Bone rafting, Val = Valgization, F/U = Follow-up

Radiographic evaluation included anteroposterior, lateral, and adduction–abduction anteroposterior radiographs, except in patients with hypermobility (n=3) [Figure 2 a,b]. All the patients were subjected to surgical treatment.

Operative procedure

Surgery was performed with the patients in the supine position on a fracture table under an image intensifier. A lateral approach to the proximal femur was used. Pseudarthrosis, which was present in three cases, was excised. The fracture ends were freshened and curetted to remove all intervening soft tissues in all cases. The end point of curettage was bleeding bony points at both ends of the nonunion. The fragments were approximated, keeping cancellous bony chips in between them. A guidewire was passed parallel to the neck. The position of the guidewire was checked under the image intensifier. It had to be central or slightly posterior in the lateral view and central or inferior in the AP view. Another guidewire was passed parallel and proximal to the first one as a transfixation wire to prevent rotation of the head during reaming. The appropriate size lag screw was inserted after reaming. The excision of pseudarthrosis, alignment of proximal and distal fragment after closure of fracture gap with cancellous bone graft are

the sequence of steps. The pseudoarthrosis is exposed from anterior aspect and usually anterior, superior and inferior freshening of fracture ends are performed. The freshening of fracture ends leave a concave fracture surfaces. When the fracture gap is closed by internally rotating the lower limb after inserting cancellous bones in nonunion site, it increases the femoral neck anterversion. The reduction look good in AP view [Figure 4] but on lateral view the neck shaft angle is reduced. As a result the nicely placed guide wire in AP view is usually not in acceptable plane on lateral view. Therefore the attempt should be made to perform 360° release of fracture surfaces. The limb should be aligned in acceptable position in AP and lateral view with neck shaft angle of 130-135° in AP view and 165-180° in lateral view. The fracture gap should not be closed by rotation of the limb but by inserting coupling screw on hip screw.

A 135° dynamic compression plate of the appropriate size, holding at least 8–10 cortices in the distal fragment, was homed in. The plate was stabilized with cortical screws, with the distal screw first giving a stable fixation with the femoral shaft. The space on medial aspect was opened after application of the 135° plate used for maintaining valgization. Compact cancellous bone graft taken from the ipsilateral iliac crest was filled in the space created on the medial aspect in all the cases. We used DHS (Sushrut, Mumbai, India,) in all the cases. The wound was closed in layers.

Postoperatively, upper tibial pin tractions with the knee in 15° of flexion was maintained for 3 weeks. Quadriceps strengthening and knee bending exercises on traction were initiated from day 1. Axillary crutch walking with toe touch was started at 3 weeks. Full weight bearing was started when clinical and radiological union was achieved. Patients were followed up at the outpatient department (OPD) at 6-week intervals till union occurred and then at 6-monthly interval. Clinical and radiographic healing processes were recorded.

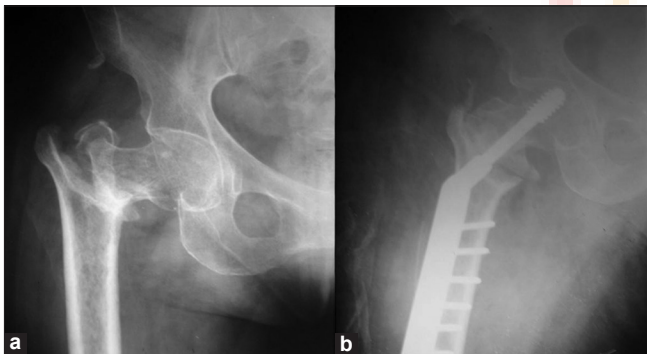


Figure 3: X-ray right hip anteroposterior view 6 1/2 months after injury showing (a) nonunion (b) 6 weeks after surgery

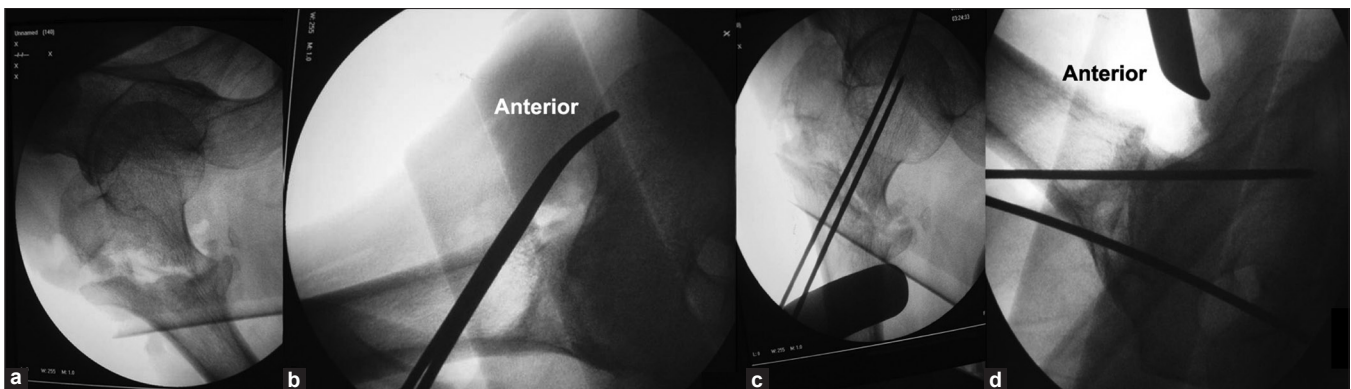


Figure 4: Fluoroscopic view of right hip joint in a patient presented after 4.5 mo of injury showing (a) reduction in intertrochanteric fracture in anteroposterior view, (b) reduction in lateral view 140° neck shaft angle which is not acceptable in this view, (c) guide wires in anteroposterior view are in superior quadrant, (d) guide wires in lateral view are in posterior quadrant

Harris hip score was recorded for each patient at healing. Union was presumed to have occurred when the patients experienced no pain or tenderness and could walk without aids and when, radiographically, trabeculi/callus bridged the two fragments.

RESULTS

Three patients had hypermobile nonunion and 15 had stiff nonunion. The neck–shaft angle at presentation to us was 90°–116° (mean: 97.2°). The limb was in external rotation in all cases. Mean shortening was 3.2 cm (range: 2–4 cm).

Mean operative time was 152 min (range: 116–172 min). Mean blood loss was 1200 ml (range: 700–1600 ml). There were no intraoperative or immediate postoperative complications. Mean follow-up was for 4.44 years (range: 2–8 years). Union was achieved in all patients at an average of 5.62 months (range: 4–7 months) [Figures 1b, 2 c,d]. Mean postoperative neck–shaft angle measured after union was 127° (range: 115°–130°). The average varus collapse was 7.5° (range: 5°–20°)

The preoperative mean active flexion was 40° (range: 30°–70°), which improved to mean of 110° (range: 90°–120°). The Harris hip score¹³ improved from 38 points preoperatively to 86 postoperatively at healing. The average limb shortening improved by 2 cm (range: 1.5 cm–3 cm).

Pin tract infection occurred in one patient but healed with removal of the pin, lavage, and antibiotics. One patient achieved union after 7 months after repeat bone grafting at 5 months. There was no infection or pain at the hip at final follow-up in any of the cases. All patients were subjectively satisfied with the outcome. All of them were capable of full weight bearing on their affected limb.

DISCUSSION

Nonunion of intertrochanteric fractures is uncommon as these fractures tend to occur through well vascularized cancellous bone.^{1,7,12–15} When nonunion does occur, it is usually in patients with unfavorable fracture patterns, poor bone quality, or suboptimal position of internal fixation devices.¹⁴ Nonunion of these fractures cause considerable morbidity and at times mortality.^{7,14} The incidence of nonunion in patients with intertrochanteric fractures is reported to be 1–2%.¹⁵ A large number of patients in the Indian subcontinent seek treatment from traditional bonesetters, who mainly use local herbal application and inadequate splinting in the treatment of these fractures. Consequently, many fractures result in malunion and a few in nonunion in adult and pediatric patient populations.¹⁶ In

the present series, 11 patients had conservative treatment in the form of traction, resulting in nonunion; 3 patients were treated by osteopaths; and 4 patients took no treatment.

A diagnosis of primary intertrochanteric nonunion is made when at least 15 weeks after the fracture there is radiological evidence of a fracture line, with either no callus (atrophic) or with callus that does not bridge the fracture site (hypertrophic) and mobility of the fragments on examination under an image intensifier.⁸ We included preoperative adduction and abduction views in all the cases. Most of the reported nonunions have followed unsuccessful attempts at operative stabilization of fractures.^{6,7,9,11,14} The factors resulting in primary nonunion have not been dealt with in any study due to the rarity of nonunions and because of ethical issues. Only one series exclusively describes seven primary nonunions of intertrochanteric fractures,⁸ five of the patients in that series had Tronzo type 4 fractures, with a large posteromedial fragment.⁸

An unfavorable pattern of fracture has been mentioned in earlier series as a cause of fixation failures. Most failures of treatment occur in unstable fracture patterns in which posteromedial cortex remained wide apart^{7,9,11,14} or the fracture is reverse oblique.⁶ Bartonicek *et al.* had 15 cases of varus malunion and nonunion of trochanteric fractures with two primary nonunions.¹¹ Nine had AO 31A2 and five had A3.3 type of unstable peri- and intertrochanteric fracture. One case was unclassified. They were treated by valgus intertrochanteric osteotomy. The authors concluded that valgus intertrochanteric osteotomy is an effective procedure that reliably restores hip function in trochanteric malunion or nonunion. Malkani *et al.* concluded that fractures that are prone to nonunion include those that are severely comminuted and unstable, with loss of medial calcar bone and a tendency to go into varus.¹⁷ Said *et al.*¹⁸ presented 23 cases of fixation failures in which 11 had A2 type fracture, 8 had A1 type fracture, and 3 had A3 type fracture; 1 case was not classified. However, both series had implant failures.

The study of muscular anatomy in an intertrochanteric fracture reveals that, with comminution, the iliopsoas tends to displace the lesser trochanter and the neighboring posteromedial cortex proximally and anteromedially. Also, the adductors play a pivotal role in the varus position in these fractures as neither their origin nor insertion is disrupted. Biomechanical studies have proven that these factors lead to high bone stresses and increased mechanical failure.¹⁹ In our series, the maximum incidence of nonunion was in AO type 2.3 (9 patients) and AO type 2.2 (3 patients). In these (AO 2.2 and 2.3 type) fractures the fracture line is partially intra-articular and partially extra-articular, with medial

Table 2: Comparison with available literature of primary intertrochanteric nonunion

Author / Year	No. of patients	Delay in presentation	Treatment	Follow-up	Complications
Weber and Cech ¹⁰ (1976)	3	Not mentioned	Comments on valgization DHS/blade plate fixation	36–72 months	-
Sarathy <i>et al.</i> ⁸ (1995)	7	15–28 weeks	Modified medial displacement and valgus osteotomy	12–36 months	None
Bartonicek <i>et al.</i> ¹¹ (2003)	2	4–6 months	VITO+IR	73–84 months	None
Present series	20	4–18 months	DHS+ valgization+BG	1.8–8 years	None

comminution leading to instability as well. Four cases had AO type 3.3. This type had a large posteromedial fragment with lesser trochanter which had constant pull of iliopsoas.¹² These two factors are probably responsible for nonunion in most of our cases. Thus, we believe that primary nonunion occurs in unstable comminuted fractures with loss of medial support and in fracture patterns where the fracture line is partly intra-articular and partly extra-articular. Mariani and Rand in study of 20 patients of fixation failures found that 19 out of 20 nonunions occurred in patients who had unstable fractures with loss of medial calcar continuity.⁷

There is a paucity of published studies on the treatment of primary intertrochanteric nonunions^{8,10,11} [Table 2]. The available literature suggests that a variety of different implants may be used successfully to treat intertrochanteric nonunion and stable fixation of the proximal fragment. Weber and Cech described five trochanteric nonunions, three of them after nonoperative treatment and two after surgery, but did not classify primary fracture patterns.¹⁰ Sarathy *et al.* reported results of seven nonunion after native splintage and traction treated successfully by a combination of valgus osteotomy, medial displacement, and 130° blade plate fixation.⁸ In treatment of nonunion from fixation failures of intertrochanteric fractures, DHS with cementation, medial displacement osteotomy, valgization, and blade plate fixation have all been reported.^{8,10,11} These studies confirm that union can be achieved both in primary nonunions and nonunions after implant failure with revision internal fixation for physiologically younger patients with good remaining bone stock.

The technique of valgus intertrochanteric osteotomy for different diagnoses (osteoarthritis, post-traumatic nonunion and malalignment, postdysplastic deformity, avascular necrosis of the femoral head, adolescent coxa vara) was developed by a number of authors.¹¹ Ballmer *et al.*²⁰ evaluated a group of 10 patients (four men, six women) with trochanteric fracture. Six patients had nonunion while four had malunion. The interval from injury to osteotomy was 13 months (range: 2–37 months). They performed valgus intertrochanteric osteotomy; however, for the fixation, they used a 120° double-angled blade in nine cases. They achieved fracture union; however, three cases

required further revision surgery (total hip replacement). They reported a success rate of the primary surgery of only 60% but did not specify the period of follow-up.²⁰ Marti *et al.*²¹ reported 24 cases of patients from different centers with peritrochanteric nonunion. They used osteotomy with different types of angled blade plates for the fixation of the osteotomy. However, the authors did not present any detailed information and results.²¹

In most cases of primary nonunions of intertrochanteric fractures, the fracture collapses into varus with shortening. The amount of correction desired is dependent on the existing deformity and the patient's preoperative neck-shaft angle (as seen on the normal side). The average varus collapse in our series was 7.5° (range 5°–20°). We used DHS in all cases of primary nonunions. We did not opt for osteotomy because the 135° DHS resulted in valgization of the femoral neck-shaft junction because all our cases had a preoperative varus nonunion. Bone grafting with freshening of bone ends was done in all cases. The critical point in the surgery is the insertion of the lag screw. It should be preferably in the posteroinferior sector of the femoral head, where we think the best bone stock is available. Release of the medial soft tissues (mainly the articular capsule and iliopsoas tendon) at the level of lesser trochanter considerably facilitates reduction of the fragments, including lateral displacement. If this medial soft tissue release is done carefully, close to the insertion, it does not impair vascularization of the femoral head. The medial opening after valgization is filled with corticocancellous bone graft always.

The treatment of intertrochanteric nonunion is guided by the age of the patient. In older patients with low-demand activities and poor bone quality or a damaged hip articular surface, arthroplasty allows earlier patient mobilization and greater certainty of outcome. Our study had physiologically young patients (mean age of the patients was 46.9 years) with long life expectancy with well-preserved femoral head. Our study affirms that in cases with good bone stock, union in primary nonunion of intertrochanteric fractures can be achieved with internal fixation, valgization, and grafting procedures.

REFERENCES

1. Angelini M, McKee MD, Waddell JP, Haidukewych G, Schemitsch EH. Salvage of failed hip fracture fixation. *J Orthop Trauma* 2009;23:471-8
2. Baumgartner MR, Solberg BD: Awareness of tipapex distance reduces failure of fixation of trochanteric fractures of the hip. *J Bone Joint Surg Br* 1997;79:969-71.
3. Kyle RF, Gustilo RB, Premer RF: Analysis of 622 intertrochanteric hip fractures. *J Bone Joint Surg Am* 1979;61:216-21.
4. Baker HR. Ununited intertrochanteric fractures of the femur. *Clin Orthop Relat Res* 1960;18:209-20.
5. Boyd HB, Lipinski SW: Nonunion of trochanteric and subtrochanteric fractures. *Surg Gynecol Obstet* 1957;104:463-70.
6. Haidukewych GJ, Israel TA, Berry DJ. Reverse obliquity of fractures of the intertrochanteric region of the femur. *J Bone Joint Surg Am* 2001;83:643-50.
7. Mariani EM, Rand JA. Nonunion of intertrochanteric fractures of the femur following open reduction and internal fixation: Results of second attempts to gain union. *Clin Orthop Relat Res* 1987;218:81-9.
8. Sarathy MP, Madhavan P, Ravichandran KM. Nonunion of intertrochanteric fractures of the femur. *J Bone Joint Surg Br* 1994;77:90-2.
9. Wu CC, Shih CH, Chen WJ, Tai CL: Treatment of cutout of a lag screw of a dynamic hip screw in an intertrochanteric fracture. *Arch Orthop Trauma Surg* 1998;117:193-6.
10. Weber BG, Cech O. *Pseudoarthrosis*. Bern: Huber; 1976. p. 181-4.
11. Bartoníček J, Skála-Rosenbaum J, Dousa P. Valgus intertrochanteric osteotomy for malunion and nonunion of trochanteric fractures. *J Orthop Trauma* 2003;17:606-12.
12. Fracture and dislocation compendium. *Orthopaedic Trauma Association Committee for Coding and Classification. J Orthop Trauma* 1996;10(Suppl 1):1-154.
13. Harris WH. Traumatic arthritis of the hip after dislocation and acetabular fractures: Treatment by mold arthroplasty: An end-result study using a new method of result evaluation. *J Bone Joint Surg Am* 1969;51:737-55.
14. Haidukewych GJ, Berry DJ. Salvage of failed internal fixation of intertrochanteric hip fractures. *Clin Orthop Relat Res* 2003;412:184-8.
15. Altner PC. Reasons for failure in treatment of intertrochanteric fractures. *Orthop Rev* 1982;11:117.
16. Mukherjee SK, Jain V. Neglected femoral diaphyseal fracture. *Clin Orthop Relat Res* 2005;431:72-9.
17. Malkani AL, Karandikar N. Revision fixation for failed intertrochanteric fractures. *Techniques in Orthopaedics* 2002;17:443-7.
18. Said GZ, Farouk O, El-Sayed A, Said HG. Salvage of failed dynamic hip screw fixation of intertrochanteric fractures. *Injury* 2006;37:194-202.
19. Gill JM, Johnson GR, Sher JL, Kornjaca NA Biomechanical aspects of the repair of intertrochanteric fractures. *J Biomed Eng* 1989;11:235-9.
20. Ballmer FT, Ballmer PM, Mast JW, Ganz R. Results of repositioning osteotomies in delayed healing or pseudarthrosis of the proximal femur. *Unfallchirurg* 1992;95:511-7.
21. Marti RK, Raaymakers EL, Nolte P, Besselaar PP. Pseudarthrosis of the proximal femur. *Orthopade* 1996;25:454-62.

How to cite this article: Dhammi IK, Jain AK, Singh AP, Rehan-UI-Haq, Mishra P, Jain S. Primary nonunion of intertrochanteric fractures of femur: An analysis of results of valgization and bone grafting. *Indian J Orthop* 2011;45:514-9.

Source of Support: Nil, **Conflict of Interest:** None.

Author Help: Reference checking facility

The manuscript system (www.journalonweb.com) allows the authors to check and verify the accuracy and style of references. The tool checks the references with PubMed as per a predefined style. Authors are encouraged to use this facility, before submitting articles to the journal.

- The style as well as bibliographic elements should be 100% accurate, to help get the references verified from the system. Even a single spelling error or addition of issue number/month of publication will lead to an error when verifying the reference.
- Example of a correct style
Sheahan P, O'leary G, Lee G, Fitzgibbon J. Cystic cervical metastases: Incidence and diagnosis using fine needle aspiration biopsy. *Otolaryngol Head Neck Surg* 2002;127:294-8.
- Only the references from journals indexed in PubMed will be checked.
- Enter each reference in new line, without a serial number.
- Add up to a maximum of 15 references at a time.
- If the reference is correct for its bibliographic elements and punctuations, it will be shown as CORRECT and a link to the correct article in PubMed will be given.
- If any of the bibliographic elements are missing, incorrect or extra (such as issue number), it will be shown as INCORRECT and link to possible articles in PubMed will be given.